Digital Impression Taking: A New Paradigm

Jordan Soll, BSc, DDS, Dip. ABAD

ABSTRACT:
Dental restorations that exhibit ease of insertion with minimal adjustments are always high on any practitioner's list. Precise fitting of restorations not only enhance a more efficient work flow but greatly contribute to optimal periodontal health. As such, an ill fitting crown, which constantly contributes to chronic gingival inflammation, creates an on going inflammatory process that will not resolve until the abnormality is corrected. Until recently the image of the prepared tooth has been captured by elastomeric materials. For more than 100 years, these impression materials have been optimized for improved replication. However, as good as the enhancements to these impression materials have been, patient comfort in the new millennium is foremost in trend design for dental products. Consequently, digitalization in the area of dental impressions has developed in full earnest. Moreover, as one can not purchase film for their camera in a convenience store, the communication of information from the dentist to the dental lab is becoming greatly enhanced by the introduction of the 3M ESPE Lava Chairside Oral Scanner. By moving from a traditional impression technique to technology that incorporates high speed image processing algorithms and real time modeling, software creates a paradigm that rivals the introduction of high speed handpieces in the 1950s.

BACKGROUND OF CURRENT IMPRESSION MATERIALS

The philosophy for today's traditional impression materials began in the mid-1930's with the introduction of reversible hydrocolloids. This was the first material that made the impression of undercuts possible. By the 1950's polysulphides were introduced and for the first time an elastomeric material was employed. Though an improvement in reproducing the characteristics of prepared teeth, there were still inherent problems throughout the product categories. The most influential problem was the shrinkage within the system. This shrinkage exhibited itself by evaporation of water within the hydrocolloid or low-molecular side products inherent in condensation cured elastomeres.

In 1965, improvements in impression materials occurred with the introduction of polyethers to the market. This material proved to be far superior to the hydrocolloid and C-type materials by way of hydrophilicity, unique flow, and setting behaviour. By 1975, silicones were introduced to dentistry. Though they are hydrophobic by nature, over time and temperature, even in the presence of a moist environment, they have a very high dimensional stability resulting in a superior elastic recovery. Over the next 40 years there have been refinements to these materials that have reduced tearing, improved patient comfort, and reduced chair time.

CURRENT TRENDS IN DIGITAL IMPRESSIONS

Today's impression materials are precise, fast, hydrophilic and can be easily dispensed. Yet, with all the improvements there are still challenges, including; the affect of temperature and the inconvenience of the patient still required to keep the filled tray in their mouth for some seemingly long minutes. Consequently, digital approaches were created to circumvent the traditional obstacles of the existing impression materials.



FIGURE 1 — LAVA Chairside Oral Scanner.

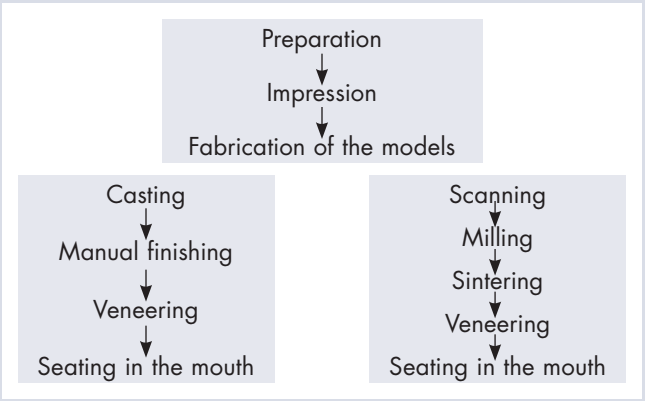

FIGURE 2 — Flow chart comparing traditional impression taking with the sequence of digital scanning.



FIGURE 3 — Pre-operative buccal view.



FIGURE 4 — Pre-operative occlusal view.



FIGURE 5 — Idealized diagnostic wax up.



FIGURE 6 — Prepared teeth just prior to scanning.

The first optical impression unit was introduced by Sirona Dental Systems under the Cerec name. The principle is based on a "point and click" technology which strings together a number of individual pictures of the same object. More recently, 3M ESPE has introduced the Lava COS (Chairside Oral Scanner) system. The main improvement to the original digital scanner is the use of 3D-in-motion technology. This technology, in contrast to the "point and click" systems, captures continuous 3D video images and displays these images in real time on a touch screen monitor. (Fig. 1)

Once the image is captured and stored, it is then electronically transferred to the dental laboratory where a technician digitally cuts and marks the margins. Subsequently, models for the case are fabricated using a technology known as Stereolithoghraphy, which allows the technician to complete the restoration. If the prescription calls for an all ceramic restoration with a Zirconium core such as Lava (3M ESPE), the core is also milled from the digital impression and the digitally produced model is used for final layering of porcelain. (Fig. 2)

CASE REPORT

A 41-year-old healthy female, with no contributing medical abnormalities, presented with unsightly lower anterior teeth, #s 32, 31, 41, 42. X-ray and clinical examination revealed a large composite restoration in the distal of tooth 41. (Fig. 3, 4) Periodontal health was excellent and there was adequate bone height present, and no mobility detected. The patient's goal was to improve the alignment, colour and uniformity of the lower front incisors.

To achieve a result that exceeded the patient's expectation in a long term predictable fashion, the treatment plan that was presented recommended the following;

- Diagnostic wax up to visualize the final outcome and illustrate the pathway for the restorations. (Fig.5)

- As the existing restoration was very large and close to the pulp, referral for prophylactic endodontic treatment on tooth #41 prior to beginning the work to avoid future problems.

- Placement of an all-ceramic crown on tooth #41 and porcelain veneers on teeth #'s 32, 31, 42.

At the consultation appointment the above treatment plan was presented using pre-operative photographs, diagnostic models, wax-up and x-rays.

After addressing the patient's concerns, she requested to proceed with treatment.

The patient began her case by completing 10 sessions of



FIGURE 7 — Correct technique for using the LAVA COS.



FIGURE 8 — Scanned abutments.



FIGURE 9 — Temporization of abutments.

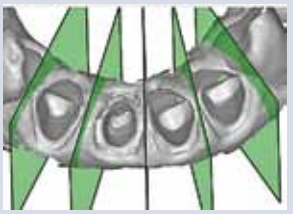

FIGURE 10 — Digital sectioning and marking of the margin.

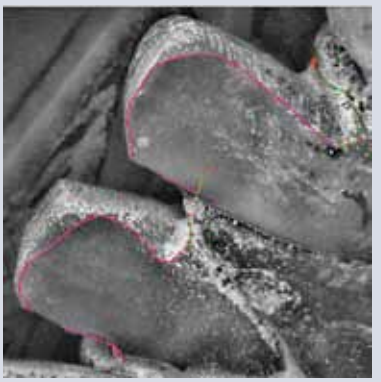

FIGURE 11 — Digital sectioning and marking of the margin.

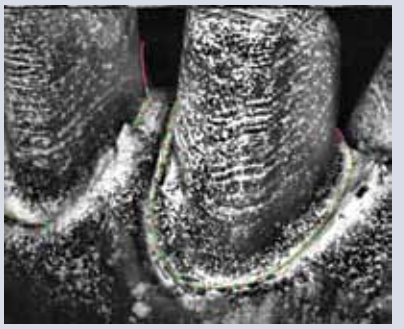

FIGURE 12 — Digital sectioning and marking of the margin.

overnight whitening with 10% Carbamide Peroxide whitening gel. (NiteWhite, Discus Dental) Subsequently, the patient was referred for endodontic therapy on tooth #41 prior to beginning the restorative phase of treatment. At the preparation appointment, tooth #41 was rebuilt with a core restoration and prepared for full crown coverage. A temporary restoration was then fabricated and the buccal was prepared, as if a veneer restoration would be placed, and then set aside until the temporization segment was required. Teeth #'s 42, 31, 32 were prepared for veneer restorations. The completed preparations were air dried, the sharp edges and line angles were rounded and the restorations were inspected to insure that all margins were at the appropriate position. Prior to scanning the prepared teeth, gingival retraction/tissue management was addressed by placing 000 non impregnated cord in the sulcus around tooth #41. Subsequently, Traxodent (Premier Dental) was placed on the margins of all four preparations to assist in moisture control and tissue retraction. After 2-3 minutes the Traxodent was washed off and dried. At this time the preparations were ready for scanning. (Fig. 6)

The teeth and soft tissues were isolated and, with a Titanium-Dioxide powder, the teeth were lightly coated. This step, which takes only a few seconds, is required to provide contrast points for scanning, improve the speed of recording and enhance the recording of the 3D image. Proper technique of the Lava COS unit requires the wand, which contains the camera, to be positioned perpendicular to the teeth to be scanned. At a distance of 5-15 mm the focal point is achieved and the information automatically begins recording. (Fig. 7) Areas that have been sufficiently scanned appear white on the monitor, while areas still requiring additional recording appear pink. If the area has not been recorded, it will appear black.

This sequence allows for real time management of the scanning process. The number of teeth required in the scan, aside from the subject matter, should be the same as what the operator would gather in each situation with a traditional impression. As such, one needs to decide if a quadrant is sufficient or a complete arch is required. Once the prepared tooth and the surrounding teeth have been recorded, as well as the corresponding opposing arch, the operator is then ready to record the occlusion.

To register the occlusion the patient is required to close into maximum intercuspation and maintain that position. The upper and lower teeth are then scanned and the relationship is then recorded. Prior to completion of the process, there is an opportunity to view the teeth specifically scanned to insure that the detail of the margins were recorded a complete 360 degrees. Once done, the accompanying digital prescription pad is filled out and the



FIGURE 13 — Working models created through the Stereolithoghraphy.



FIGURE 14 — Working models created through the Stereolithoghraphy.



FIGURE 15 — Final restorations.

digital file is then emailed to the specified laboratory. (Fig 8)

When the scan is complete, prior to the patient dismissal, temporization is required. In this specific instance provisionals were placed in the following fashion. Of the four prepared teeth, three were veneers and one was a full crown. The first step was to fabricate the temporary crown. When this was complete the face was prepared, as if a veneer was to be placed, and was cemented into position. Subsequently, the buccal surfaces of 42, 31, and 32 were washed, dried, spot etched and bonded using a non filled bonding resin. Using a clear matrix, fabricated from the diagnostic wax-up, the faces of the identified teeth in the matrix were filled with a flowable resin. The matrix was then seated into position and the teeth were light cured. When the composite was set the matrix was removed, and using esthetic trimming burs (Brassler), the flash was removed and the gingival embrasures were relieved. The temporaries were adjusted for occlusion and polished. (Fig. 9) At this time post-operative instructions were given and the patient was appointed for the insertion appointment.

Upon receiving the new digital file, the laboratory is notified through their Case Manager program that a new case is ready for downloading and processing. Using a Margin Marking program, the technician digitally marks the margins of the prepared teeth and the data is electronically transmitted to 3M ESPE for the fabrication of the working models. (Figs. 10, 11, 12) The models are created from technology referred to as Stereolithography. This process uses a laser micro curing process to fabricate the models from a volumetrically stable polymer resin. This proprietary process creates a hard model from the digital file and placed in a stable friction lock articulator that is a reproduction of the patient's intercuspation. (Fig. 13, 14) As the file is stored on the Lava COS and the 3M ESPE servers there is no need for model storage once the case has been inserted. Should the models be required in the future, they can always be reproduced within short time. These restorations are then delivered back to the laboratory for completion of the restorations.

In this particular case the restorations requested were E-Max all ceramic crown and veneers. Upon return from the laboratory the restorations were checked on the model for fit, contour and finish. At the patient's visit, she was anaesthetized and the provisionals were sectioned and removed. The abutments were scrubbed with a sodium hypochlorite and pumice mixture. The finished restorations were tried in and previewed for the patient. Once the patient approved the appearance of the new restorations they were prepared for bonding into place. Using RelyX Veneer Cement (3M ESPE), the veneers were placed and cured and the all ceramic crown was cemented with RelyX Resin Cement. Once all the restorations were positioned and completely cured, all resin tags were removed using a U15 scaler and esthetic trimming burs. The occlusion was checked and relieved where required and the interproximal contacts were flossed. The appointment was concluded with polishing of the restorations with Fine and Extra Fine Diamond polishing paste. (Cosmedent) (Fig. 15) The patient was given post-operative instructions, including daily use of warm salt water rinsing to allow for gingival healing around the new restorations, to insure that proper home care was carried out. OH

Dr. Jordan Soll is a Diplomate in the American Board of Aesthetic Dentistry and Co-Chair of the Editorial Board of Oral Health.

Oral Health welcomes this original article.

ACKNOWLEDGEMENTS

The author would like to thank Mr. Trevor Laingchild of Yorkville Dental Studio for the outstanding restorations provided in this case.

DISCLOSURE

The author has received clinical support from 3M ESPE.