Expa-Syl: The Key To Making Routine Impression-Taking, Routine

By Jordan Soll, DDS

The ability to take a clear and precise impression for crown and bridge restorations is paramount to the ultimate success of the finished product. Too often there is little attention paid to this stage of the procedure. Yet a poor impression will be the basis on which the laboratory technician will fabricate the final result. Errors can lead to open margins, overhangs, thick porcelain, which can result in a poor emergence profile, and margins that are shy of the true finish line. Over time all of these built in imperfections will adversely affect the gingival complex and result in chronically inflamed gingival tissues and/or recession. According to Shillingburg the three criteria for a gingival retraction material are:

1. effectiveness in gingival displacement and hemostasis
2. absence of irreversible damage to the gingiva
3. paucity of untoward systemic effects.[1]

Gingival recession can be defined as "the exposition of the radicular surface of the tooth due to the destruction of the marginal gingiva and of the epithelial attachment that will be reestablished at a more apical position."[2] Determinant factors include:

1. bacterial plaque
2. trauma from tooth brushing
3. habits
4. iatrogenic injuries.

One example of an iatrogenic injury is the improper use of retraction cord or electrosurgery in preparation for impression-taking.[3] It is the mechanical disruption of the dentogingival complex which results in the severing of the attachment fibers and subsequent recession. According to Dr. John Kois, "It is imperative that the base of the sulcus is determined so that cervical limitations of tooth preparation are defined." Violation of the sulcular base and/or the biological width is "the single most important factor in determining

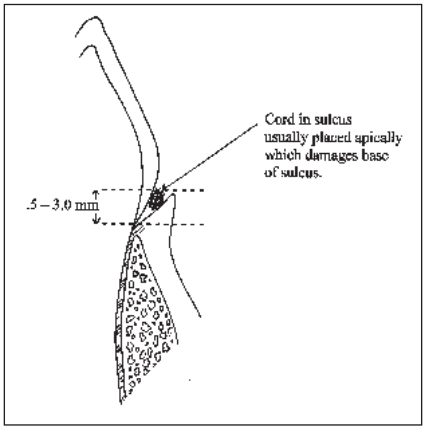

FIGURE 1 Schematic drawing of retraction cord in sulcus. Note that downward pressure can cause violation of the biologic width and result in migration of the margin.



FIGURE 2 Retraction cord being placed into sulcus.

Formulation of Expa-syl

Description	Wt%
Kaolin	66.75
Aluminium Chloride	6.54
Water	25.36
Essential oil of lemon	0.33
Eolorant (E102 + E131)	1.02

pH of Expa-syl = ~3

FIGURE 3

the gingival response in restorative dentistry."[4] (Figs.1 & 2)

Consequently, it is of the utmost importance that the process of impression-taking be done with as little disruption to the sulcus as possible. In addition, the choice of all ceramic restorations and the frequent use of CAD/CAM milling for their preparation makes the need for an exact impression more important than ever.

PRODUCT PROFILE

The success of crown and bridge impression applications is dependent upon taking accurate impressions. More crowns fail due to faulty marginal fit caused by poor impressions than from all other causes combined. The need for rapid and predictable tissue management is critical. Expa-syl (Kerr Corporation, Orange, CA.) is a new material (to the best of the author's knowledge the only such product of its type) to assist the dentist with taking routine crown and bridge impressions quickly and accurately.

Expa-syl is a viscous paste that acts as a hemostatic and retraction agent. It contains aluminum chloride and kaolin. Kaolin is a clay-like substance that is dense and stable. This paste acts the same as pressure applied to a wound. Combined with aluminum chloride, excellent hemostasis is attained. Additional ingredients include water, essential oil of lemon, and colourants (Figs. 3 & 4). Retraction is provided via the dense nature of the paste. Once applied the material remains unchanged. There is no chemical reaction, material expansion, or setting. Perhaps most importantly, there is no damage to the epithelium that can lead to gingival recession, crevicular leakage (tissue fluid other than blood) or bone resorption.

Comparison of commonly used hemostatic agents.

Hemostatic Agent	Acidic pH Level	Provides Hemostasis Through	Important Features
Aluminum Chloride	3 plus	Constriction of tubules	Least reactive of the hemostatic agents with polyvinyl impression material.
Ferric Sulfate	1.2	Cauterizing tissue	Turns tissue black. Bleeding after cord removal likely. May inhibit the set of impression material, must rinse thoroughly. Tastes like acid. Widely used. Compatible with Expa-syl.
Aluminum Sulfate	3 plus	Constriction of tubules	Offensive taste.
Zinc Phenol Sulfate	3 plus	Constriction of tubules	To reduce the level on Epinephrine and provide dual action manufacturers will mix this in.
Epinephrine	Neutral	Vaso-constrictor	Increases heart rate of patient, therefore, depending on patient and the amount of it present in larger cords, must use with caution.

FIGURE 4

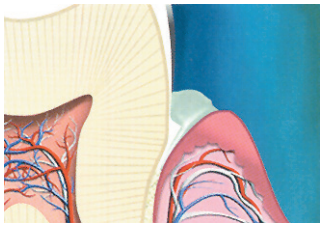

FIGURE 5 Schematic drawing of Expa-syl in Sulcus.

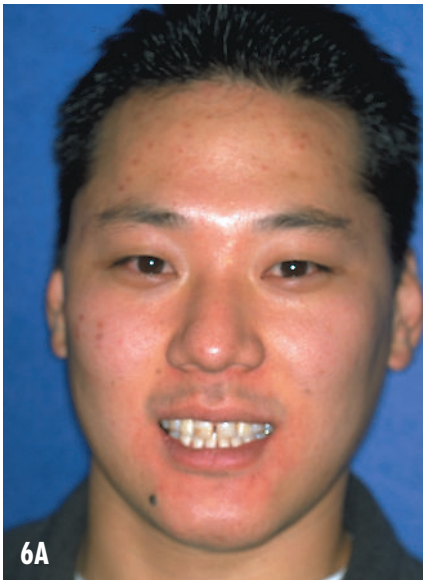





FIGURES 6A, B & C Pre-operative appearance of patient.

Expa-syl is supplied in cartridge form that conveniently fits into a high quality stainless steel dispenser and utilizes accompanying disposable tips. To use the material, extrude Expa-syl into the sulcus around the preparation, which usually takes 15-45 seconds depending on the restoration (Fig. 5). Once the material is in place leave it there for 1-2 minutes then rinse it off vigorously with sufficient air/water spray to clear away all the material. The resultant hemostasis and retraction will allow you to take a precise impression. This technique is exceptional for anterior aesthetics where gingival creep can otherwise ruin a well-thought-out and executed case.

Additional benefits of this material include:

1. Addresses issues of medically compromised patients (eliminates need to place cord impregnated with epinephrine).
2. Greatly reduces operator time. This holds even greater value if Expa-syl is employed during the cementation phase.
3. Eliminates problematic sulcular bleeding that could begin during cord removal, due to the disruption of the residual coagulative hemostatic agents.
4. Improves aesthetics. Unlike many astringents, Expa-syl does not include ferric sulfate, which is known to cause black lines on the tissue at the margin.





FIGURE 7A & B Preparation of the maxillary front 8 teeth. Note that the contacts were separated and the finish lines were on the lingual line angle.







FIGURE 8A, B & C Placement of Expa-syl on the gingival sulcus and subsequent rinsing.

CASE STUDY

A 30-year-old male in good medical health presented with the chief complaint of dissatisfaction with the appearance of his smile (Figs. 6a, b & c). The patient's specific concerns were that he was displeased with:

1. The space between his front teeth
2. The staining and loss of smooth texture of his teeth
3. The overall shape of his front teeth

After recording the patient's initial concerns a thorough cosmetic evaluation was completed utilizing the Strategic Esthetic

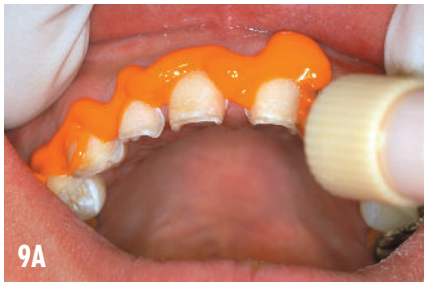

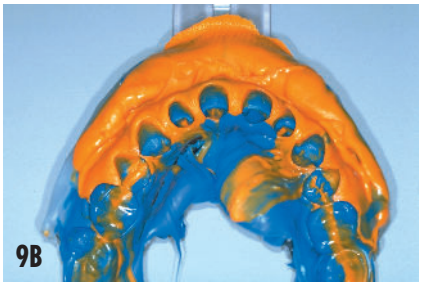

FIGURE 9A & B Impression of prepared teeth.







FIGURE 10A, B & C Spot etch technique using Point 4 to create temporary veneers.

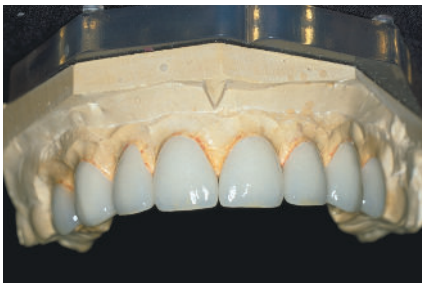

FIGURE 11 Veneers checked on model for fit and contour.





FIGURE 12A & B Isolation of the maxillary arch and cleaning of the prepared teeth.

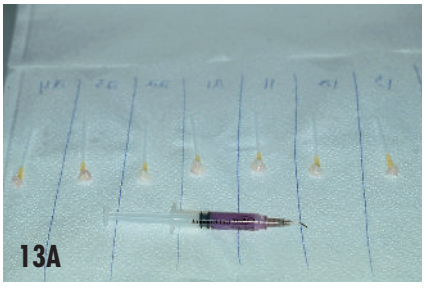



FIGURE 13A & B The assistant systematically preparing eight (8) veneers for insertion.



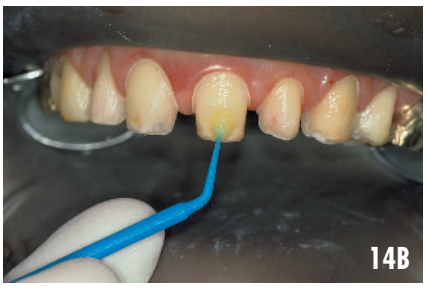

FIGURE 14A & B All abutments are etched and rinsed. Gluma Desensitizer is used as a wetting agent prior to the bonding and luting agents



FIGURE 15 Veneers being sequentially placed with excess luting resin being drawn away with a rubber tip.

Planning Guide.[5]

Analysis showed that bilaterally the second premolar teeth were missing and that there was excessive arch space available yet the patient was classified as class I occlusal. In addition gold crowns present on all 4 first molars contributed to an unaesthetic look. Correcting the appearance of the patient's smile called for the following 2-phase treatment plan: phase I placement of 8 porcelain veneers, phase II (when the patient's finances would allow) placement of PBM crowns on all 4 first molars. With the patient's approval of the plan we proceeded with treatment.

The patient was anaesthetized and tooth #'s 14-24 were prepared for porcelain veneers using the Brassler Porcelain Veneer kit (Brassler Savannah, GA.). To overcome the additional space in the maxillary arch and create the illusion of a well-proportioned dentition, the distal contacts of 13-23 were broken. This allowed the original diastema to be spread out over the 8 anterior teeth and therefore have minimal change to the length and width ratio of the existing teeth (Figs. 7a & b). All preparations had margins that wrapped around the mesial and distal and finished at the lingual line angles. This was done so that the technician could create the new contact points in porcelain and to ensure a suitable emergence profile. Once the preparations were completed they were examined dry for any irregularities prior to the impression-taking process.

All teeth were dried and Expasyl was applied to the sulci so that all 8 teeth had the clay-like material around approximately 80% of their circumferences. The Expasyl was allowed to stay in place approximately 2 minutes and then rinsed off with copious amounts of water (Figs. 8a, b & c). After rinsing off the retraction material the sulci were examined and found to be retracted and free of moisture. Subsequently the overall impression was taken using a polyvinyl siloxane material such as Take One (Kerr Corporation, Orange, CA.). The impression was examined and found to be free of voids with the margins captured in perfect detail (Figs. 9a & b).

To protect the dentition, ensure comfort, and maintain the aesthetics of the case, temporary veneers were created using the spot etch

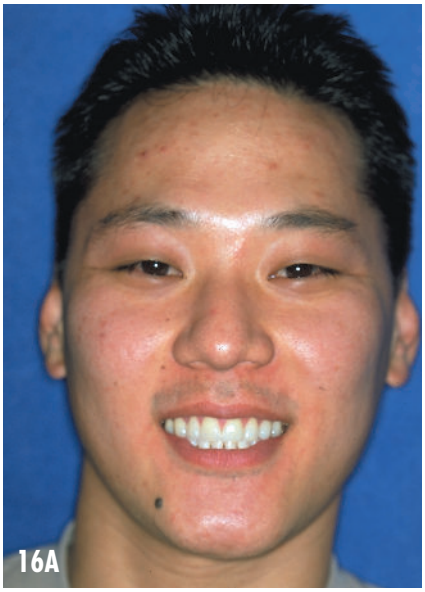





FIGURE 16A, B & C Post-op appearance of completed case.

By removing one more factor that could contribute to failure in aesthetic cases, Expa-syl can become a new invaluable tool in the cosmetic dentist's armamentarium.

technique and a small particle hybrid called Point 4 (Kerr Corporation, Orange, CA).[6] Point 4 was used because it provides the combination of strength and aesthetics that is ideal for temporary veneers (Figs. 10a, b & c).

Upon their return from the laboratory, the veneers were checked on the model for fit and contour (Fig. 11). The patient was then anaesthetized and the veneers were tried in for fit, colour, and patient approval. With the patient confirming his acceptance of the veneers and requesting them to be bonded in, the maxillary arch was isolated and cleaned with a sodium hypochlorite and pumice mixture (Figs.12a & b).

The bonding process occurred simultaneously, with the assistant laying out the 8 veneers and preparing them for bonding which included removing the try-in paste, etching, and applying silane and bond (Figs. 13a & b). At the same time the 8 abutments were cleansed of the try in paste, etched, and thoroughly rinsed and dried. Gluma (Heraeus Kulzer, South Bend, IN) was used as the wetting agent and Solo Plus in conjunction with Nexus II was used as the bonding agent and luting resin (Kerr Corporation, Orange, CA).

The 4 anterior veneers were bonded in first and together. The excess material was removed with a rubber tip and the veneers were then cured (Fig. 15). The canine and premolar bilaterally were then placed into position in a similar fashion. The 8 restorations were then completely cured, margins checked for excess resin, occlusion checked and adjusted, and polished.

CONCLUSION

The post-operative examination of the completed case revealed a vastly improved appearance of the maxillary arch (Figs. 16a, b & c). In addition the gingival tissues showed no signs of creep or inflammation 8 weeks post insertion. Often, creep is noticed between the impression appointment and the insertion appointment. Though Expa-syl is not indicated for every impression scenario, most situations where there is a dry field are ideal for this new and innovative product. By removing one more factor that could contribute to failure in aesthetic cases, Espa-syl can become a new invaluable tool in the cosmetic dentist's armamentarium. **OH**

Jordan Soll is Oral Health's editorial board member for Cosmetic Dentistry.



The author acknowledges Koh Eng Joo of Supreme Dental Ceramics for his outstanding artistry on this case.

Oral Health welcomes this original article.

REFERENCES

1. Fundamentals of Fixed Prosthodontics 3rd Edition Herbert T. Shillingburg Jr. Quintessence Books, Chicago Page 261.
2. Fundamentals of Esthetics Claude R. Rufenacht Quintessence Publishing Co., Chicago Pages 237-238.
3. Fundamentals of Esthetics Claude R. Rufenacht Quintessence Publishing Co., Chicago Pages 237-238.
4. Creating Restorative Excellence: The Biologic Connection John C. Kois Classic Dental Laboratories News Letter March 1995.
5. Strategic Esthetic Planning for Predictably Successful Results Jordan L. Soll, Oral Health, April 1997 Page 35-43.
6. Information Provided at Post Graduate Program of Esthetic Dentistry Jeffrey Morley State University of New York – Buffalo Campus December 3, 1994 .