Vital Tooth Whitening: Slow and Steady Wins the Race

by Jordan Soll, DDS

The ability to improve the appearance of one's smile by nightguard vital bleaching (or at-home bleaching) has been accepted in North America since 1989.[1] With a greater degree of research being carried out and the results favorable when the technique is adhered to, tooth whitening has become one of the most conservative forms of aesthetic dentistry available.[2,3] Though whitening is widely accepted and is almost regarded as fashionable, the concept is not new. The earliest attempts to whiten teeth occurred more than 100 years ago. The original agent used was oxalic acid, which was applied directly to the teeth. The first application of hydrogen peroxide, which at that time was referred to as hydrogen dioxide, was used in 1884.[4] By the early 1900s it was firmly established that hydrogen peroxide held the best chance of success. As a result, dentists began to focus their attention on hydrogen peroxide as the whitening agent of choice. In 1918, it was discovered that the use of a high intensity light to raise the temperature of the hydrogen peroxide accelerated the chemical reaction and enhanced the bleaching process.[5]

Through empirical data and trial and error, contemporary whitening has evolved to the placement of a weaker bleaching agent having intimate contact with the tooth surface over a longer time period. This is achieved by placing the solution in a reservoir-like retainer. The material of choice is carbamide peroxide, which is usually prescribed in 10%, 16%, or 20% strengths. Carbamide peroxide is far more stable and longer lasting than hydrogen peroxide. A 10% solution of carbamide peroxide is composed of 7% urea and 3% hydrogen peroxide. When combined with anhydrous glycerin, a 10% compound of carbamide peroxide is equivalent to a 3% solution of hydrogen peroxide, yet exhibits greater efficacy in the presence of oral tissues.[6]

The basis for the whitening process involves the principle of oxidation whereby the hydrogen peroxide penetrates the tooth structure and causes the mole-





FIGURES 1 & 2 Tooth #21 stands out in the smile as being darker than the adjacent teeth.

cules containing the stain to be released. The degree of success is dependent on:
– the cause of the stain
– the location and length of time the stain has been there
– the ability of the whitening agent to penetrate the tooth structure
– the length of time the agent is in contact with the stain[7]

Investigative reports by NBC's Dateline[8] and ABC's 20/20[9] have shown that commercially-available whitening products do not work very well. Due to their low cost and ease of purchase, these "over the counter" products have had a mass market appeal. Because the public is not aware of the factors that result in a predictable outcome, they are easily influenced by the media and motivated to make a low-cost low-result investment.

To ensure a successful result the patient should be properly diagnosed before proceeding with whitening. This would include a thorough medical history, oral examination, and a complete scaling and prophylaxis. It is also important to determine the origin of the offending stains. They would fall into two groups:

Extrinsic
1) tobacco
2) food
3) topical medicines

Intrinsic
1) pre-eruptive (tetracycline, nutritional deficiencies)
2) post-eruptive (local effects of filling materials)

Record the pre treatment shade both visually (usually with instant photography) and in writing in the patient's chart. To achieve maximum compliance and results, give complete whitening instructions as well as a thorough demonstration. Before beginning the whitening process, determine the patient's expectations. Monitor the treatment by scheduling assessment visits until the treatment is complete. It is customary, though not necessary, to recommend to the patient whitening one arch at a time. This is helpful because the patient can observe how well the whitening process is working by comparing the two arches. As well, if the patient has any sensitivity they will only have sensitivity on one arch at a time.



FIGURE 3 Radiographic evaluation reveals that #21 pulpal chamber is completely calcified.

HOME SYSTEMS VS. IN-OFFICE SYSTEMS

Many practitioners are eager to encourage their patients to try laser whitening because of the connotation that it holds of a "high tech" advantage over their colleagues. However, in doing so, they have not revealed complete current research information to their patients. Using "marketing sizzle" rather than substantiated fact only leaves the consumer disappointed.

When comparing the efficacy and predictability of laser whitening versus home whitening, laser whitening does not offer any advantages and usually costs more. Although there is no advantage to using laser whitening on its own, it does have a purpose when incorporated into the treatment plan of "Dentition Bleaching." This conclusion has been borne out in unbiased testing.[10,11]

Through Clinical Research Associates, Gordon Christensen's



FIGURE 4 #21 is isolated and prepared using a 3% solution of hydrogen peroxide and pumice.



FIGURE 5 Chairside whitening using Shofu Hi-Lite is applied to #21 to "jump start the treatment."

investigations revealed that there is no perceivable difference between energized versus non energized treatment when the same bleach and concentration was used for the same period of time. The report goes on to state, "addition of light or heat provides positive psychological stimulus for patients and adds flair to the procedure, but the data does not show increased liberation of active ingredient or lightening of teeth due to these stimuli."[10]

In an article by Jones *et al*, they set out to determine if there were any differences in three tooth bleaching techniques. This study compared the effectiveness of 10% and 20% carbamide peroxide and the laser activated 35% concentration of hydrogen peroxide. The study concluded that both 10% and 20% carbamide peroxide were capable of modifying tooth color. In addition, a two-week application of 20% carbamide peroxide resulted in a greater colour change when compared to a single session of in office bleaching. The protocol for the laser bleaching did not result in significant colour change and the authors suggest that the clinician should be prepared for additional applications. It was also suggested that over time the 20% carbamide peroxide holds the greatest promise for a predictable result.[11]

The above information suggests that the appropriate place for laser whitening is simply as an adjunct to "jump start" a case so the patient who is looking for immediate gratification can be satisfied. However, to insure longevity of the treatment, the patient must follow through on a regimen of home bleaching using a 10%-20% solution of carbamide peroxide. If cost is an issue for the patient, the greatest results with the least amount of expense can be derived from conventional professionally dispensed home whitening systems.

SAFETY

The issue of whitening and safety is a controversial topic to many practitioners; there are precautions that should be understood. If whitening agents are applied responsibly then they can be used with confidence. There are three issues of safety to be addressed:

1) Reduction of enamel hardness/ Change in surface morphology

In exhaustive studies involving the use of 10% carbamide peroxide, Haywood examined the effects of 1000 hours of exposure of in vitro enamel surfaces. With the use of scanning electron microscope studies, he did not find any appreciable changes. Haywood concluded, "the fear that this process will eventually dissolve away the enamel surface is not supported by current research."[12]

2) Tooth Sensitivity/Pulpal Infiltration

Research has determined that only 10% solutions of carbamide peroxide have no adverse effects on pulpal tissue. Consequently, only 10% carbamide peroxide has been approved by the ADA. In vitro and in vivo studies involving 35% hydrogen peroxide (the same ingredient used in conjunction with laser whitening) have reported irreversible pulp changes.[13] As well, there has been no significant research with higher concentrations of peroxides on



FIGURE 6 Result after 5 applications of chairside whitening material.

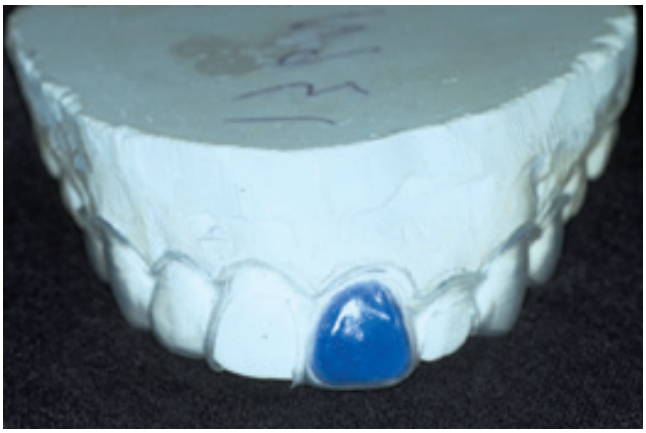

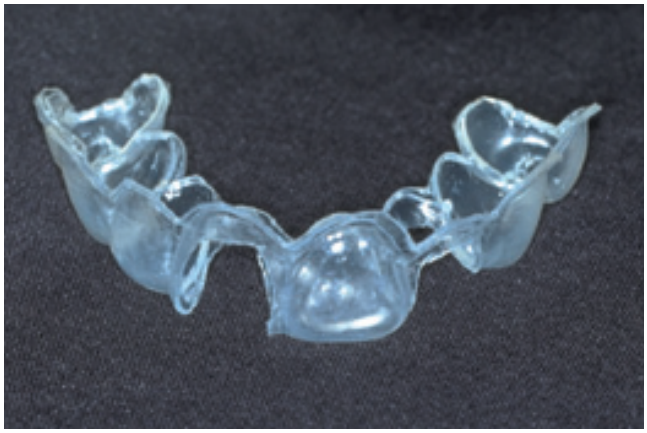

FIGURES 7 & 8 Design of whitening tray to permit at home whitening of #21 only.

teeth or pulps.[13] Tooth sensitivity is less of an issue with the introduction of potassium nitrate as an adjunct to the whitening procedure. The application of a 5% solution of potassium nitrate prior to the whitening process significantly reduces this reversible side effect.[14]

3) Long Term Effects

The active ingredient in carbamide peroxide is hydrogen peroxide, also found in humans as a normal intermediate metabolite, in which, is eventually broken down to oxygen and water. As previously discussed, a 10% solution of carbamide peroxide is reduced to 7% urea and 3% hydrogen peroxide. The human body is well equipped through the protective mucosal barriers to handle the concentrations of hydrogen peroxide that are found in 10% carbamide peroxide solutions. Moreover, material ingestion of home bleaching systems is not of concern when the products are used as recommended.[15]

CASE STUDY

A healthy 36-year old male patient presented to the office inquiring about whitening his teeth and improving his smile. He was motivated by his peers, who had commented about his "dark front tooth." A visual examination revealed a healthy dentition free of decay with minimal restorations present (Figs. 1 & 2). Radiographic evaluation of tooth #21 showed the pulpal chamber was completely calcified (Fig. 3). There was no evidence of apical pathology. The patient had advised me that he originated from Australia and when he was younger, was active in rugby. He recalled being hit in the mouth but remembered very little else about the incident. The patient's prime concern was that all his teeth would whiten except the one dark tooth.

I reviewed the technique of home whitening but cautioned that I could not guarantee its outcome because of the altered morphology of #21. It was suggested that we initiate the process by concentrating on #21 and observing the results. If the outcome was favorable then we would proceed with the rest of the dentition. The patient approved this approach and agreed to treatment.

Treatment began with one session of in office whitening that was localized to #21. The material used was Hi-Lite (Shofu; Menlo Park, CA). The active ingredient is a 35% hydrogen peroxide concentration. The absence of a visible pulp chamber, which may suggest minimal risk, was a key factor in initiating the process with a material that is known to enter the pulpal chamber and cause irreversible damage. After the tooth was isolated, it was thoroughly cleaned using pumice and a 3% solution of hydrogen peroxide (Fig. 4). Once this was done the offending tooth was treated with the Hi-Lite whitening solution (Fig. 5). To initiate the gel, a chair-side curing light was used. The author's choice was the Optilux 400 (Demetron Research Corp. Danbury, CT) because it has the capability of delivering in excess of 900 mm/cm^2. The light is activated until the bleaching material turns from a blue gel to a white powder. The white powder is removed and the gel is reapplied. This procedure was repeated 5 times during the office visit (Fig. 6).



FIGURE 9 Result of 4 weeks of home whitening on #21.





FIGURES 10 & 11 Completion of the case after an additional 3 weeks of whitening. Note that #21 was not whitened during this time.

The second stage of whitening involved the patient continuing with a 10% carbamide peroxide home whitening system (Night White, Discus Dental Canada, Peterborough, Ont.). In keeping with the patients desire to determine the degree of whitening that would result in the calcified tooth prior to committing to whitening the complete dentition, a special whitening tray was fabricated. Its construction extended from tooth 15-25 and #'s 11 and 22 were cut out so #21 would be isolated (Figs. 7 & 8). The patient was instructed to place the gel in the #21 position only and to wear as directed for 2 weeks. At this time the patient was assessed and instructed to continue the process for an additional 2 weeks. After 4 weeks #21 was re-evaluated. The significant results motivated the patient to complete stage 3 (Fig.9).

The patient was given a new tray that had the #21 position removed, and was asked to complete the process for the rest of the maxillary arch, which took an additional 3 weeks (Figs. 10 & 11).

CONCLUSION

Since its introduction in 1989, home whitening involving various preparations of carbamide peroxide, has contributed significantly to modern day dentistry and is a pillar in the cosmetic revolution. Each year there are variations on the process. It should be noted that before abandoning the tried and tested methods, we should review the literature and determine if there is validity in the process they are offering our patients.

Some practitioners are still caught in a misleading paradigm and believe that whitening, even when properly dispensed, is carcinogenic and detrimental to the patients' well being. Before depriving your patients of a treatment that may satisfy their need to improve their smiles it is important to research credible information and to make a truly informed decision. Remember, "you can't steal second with one foot still on first." — *Yogi Berra.*

Dr. Jordan Soll conceived and developed the Strategic Esthetic Planning Guide, as well as the Achieve Maximum Altitude One-Day Program. He is principal of Aesthetics in Dentistry, a group practice which emphasizes appearance-related dentistry. He also sits on Oral Health's editorial board as Cosmetic Consultant.



Oral Health welcomes this original article.

REFERENCES

1. Haywood, V.B. Historical Development of Whiteners: Clinical Safety and Efficacy Oral Health April 1999, Pg. 27
2. Haywood, V.B. et al, Effectiveness, Side Effects, and Long-Term Studies Of Nightguard Vital Bleaching, JADA 1994 (125: 1219-1226)
3. Tam, L., The Safety of Home Bleaching Technique, JCDA Sept. 1999 Vol. 65 , No. 8, 453-5
4. Goldstein, R., Garber, R., Complete Dental Bleaching, Quintessence Publishing, Chicago 1995, Pg.12
5. Goldstein, R., Garber, D., Complete Dental Bleaching, Quintessence Publishing, Chicago 1995, Pg. 13
6. McLaughlin, G. Freedman, G., The Color Atlas of Tooth Whitening, Ishiyaku Euro America Inc., St. Louis Mo. 1991, Pgs. 9-10
7. Goldstein, R., Garber, D., Complete Dental Bleaching, Quintessence Publishing, Chicago 1995, Pgs. 12-13
8. Consumer Alert: The Color of Your Smile, Dateline with Stone Phillips, NBC Television, June 18, 1999
9. Smile Makeovers, 20/20 With Arnold Diaz, ABC Television, March 5, 1999
10. Clinical Research Associates Newsletter, 1707 North Canyon Road, Suite 5, Provo Utah, USA 84604, April 1997 pg. 2
11. Jones, A. et al, Colorimetric Assessment of Laser and Home Bleaching Techniques, Journal of Esthetic Dentistry, Vol. 11, No. 2 1999, B.C. Decker Inc. Hamilton Ontario
12. Haywood et al, The Current Status of Vital Tooth Whitening Techniques, Compendium of Continuing Education in Dentistry, Dental Learning Systems, Jamesburg NJ, Pgs. 786-88
13. Tam, L., The Safety of Home Bleaching Techniques, JCDA Sept. 1999 Vol. 65 No. 8, Pg.453
14. Haywood et al, The Current Status of Vital Tooth Whitening Techniques, Compendium of Continuing Education in Dentistry, Dental Learning Systems, Jamesburg NJ, Pgs. 786-88
15. Tam, L., The Safety of Home Bleaching Techniques, JCDA Sept. 1999 Vol. 65, No.8, Pg. 454