Elements of a Make Over

Jordan L. Soll, DDS, R. Stephen Mulholland, MD, and Trevor R. Laingchild, RDT

ABSTRACT

Popular TV shows such as ABC's Extreme Make Over and The Swan, use a team of professionals who, in turn, transforms each contestant, demonstrating the individual's true potential. There must be co-ordination between contributors to insure a predictable outcome. Working independently of network production schedules can be daunting, however necessary, to insure that the patients' interests are served. This article highlights the interaction between the following: a plastic surgeon performing a rhinoplasty; a periodontist, required to insure that gingival heights of contour are in the correct position; a general practitioner with a special interest in appearance related procedures, to correct a tooth to tooth discrepancy; and the master ceramist, who will bring life to the new restorations.

The patient, a pleasant and outgoing 29-year-old female, presented as a candidate for a make-over and was to be featured on a popular, nationally broadcasted daytime Toronto talk show. She was interested in improving the appearance of her nose, harmonizing her naso-facial balance and creating a bright symmetrical smile. The process involved meeting with both the plastic surgeon and the dentist to insure that her expectations were realistic, that our operative plan and proposed aesthetic goals matched her own. Moreover, she was aware of the risks, benefits and recovery of the proposed treatments. After discussions, all parties were comfortable with proceeding. It was agreed that the sequence would proceed as follows:

The patient would have nasal-facial and dental work ups, gather all pre-operative records, and review the procedures and expected outcomes. The active treatment sequence would include gingival contouring to place the tissues at ideal heights (approximately 8-10 weeks of healing would be required and the surgeon requested that no dental work be done for a period of two months following the rhinoplasty). After healing of both the gingival surgery and rhinoplasty, the patient would be ready for the placement of 10 porcelain veneers.

DENTAL EVALUATION

The patient's main objective was to "even things out" but keep her smile "very natural looking." A comprehensive exam including an FMX, dentogram with periodontal charting, preoperative study models with subsequent wax mock up, and photographs, was completed.

A review of all the dental records revealed, overall, a healthy mouth with the need to remove the four wisdom teeth due to mal-posi-



FIGURE 1



FIGURE 2



FIGURE 3



FIGURE 4

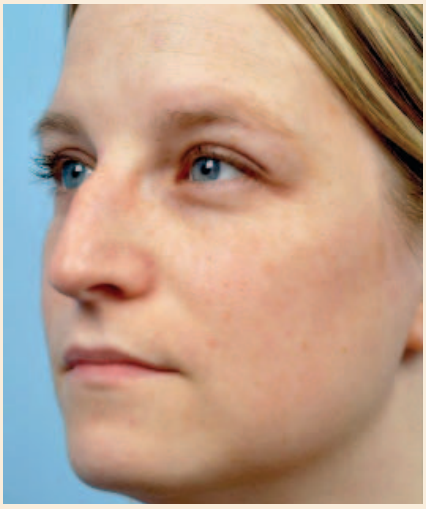

FIGURE 5



FIGURE 6

tion. From an aesthetic view point the teeth in the maxillary arch were not in an ideal relationship to each other with the 15 and 25 being palatally inclined. In addition, the gingival tissues were asymmetrical from 13 to 23 and converged low on the buccal aspects of 15 and 25 due to their positions (Figs. 1–4).

A discussion with the patient regarding options to improve the contour of the upper arch centered on either gingival contour followed by the placement of 10 veneers or on orthodontic alignment. After reviewing the risks and benefits of each option the patient decided to proceed with option one.

The following treatment plan was presented:

— Gingival contouring/crown lengthening of teeth 15/11/21/25;

— In office Zoom Advanced Power Whitening of the lower arch followed by four nights of take-home whitening (to lock in the effects of the in-office whitening);

The patient's main objective was to "even things out" but keep her smile "very natural looking"

— Preparation and placement of 10 porcelain veneers for teeth 15-25.

COSMETIC EVALUATION

The complaint the patient presented with was a long history of dissatisfaction regarding her nasal-facial balance. She was uncomfortable with the appearance in profile, specifically her dorsal nasal bridge bump, over projected nasal tip and plunging tip on smile. She felt that, since adolescence, her nasal profile had dominated her face. She had thought of having nasal surgery for many years and her goals were to improve her nasal-facial balance and achieve a nasal projection and shape that better matched her overall facial features. The patient denied any nasal functional abnormalities.



FIGURE 7

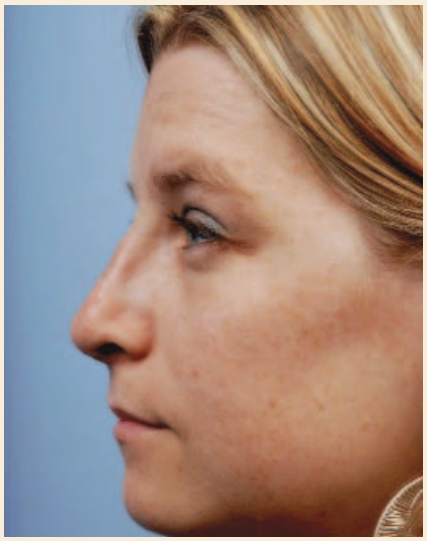

FIGURE 8



FIGURE 9



FIGURE 10



FIGURE 11



FIGURE 12

An examination revealed an over projected nasal tip, a strong nasal bridge with a convex bridge contour and a tension tip, which plunged on animation. The radix to tip length was long. In addition, there was a slight degree of microgenia and an obtuse cervical angle with focal submental lipodystrophy (Figs. 5 & 6).

After a review of the computer imaging of possible nasal contour results, and a discussion of the risks, benefits, and recovery of an external rhinoplasty, the patient elected to proceed with a reduction rhinoplasty. The patient's aesthetic naso-facial goals were to achieve a subtle reduction of the nasal bridge bump, retaining a strong bridge and not opting for mentalor malar implantation, or lipo-contouring of the submental fat.

SEQUENCE OF PROCEDURES

The transformation began with the periodontist completing crown lengthening and gingival re-contouring at the 15/25 and 12-21 positions. Using the diagnostic wax up as a guide, inverse bevel and sulcular incisions on the buccal aspect only were performed at 11, 21, 15 and 25 positions. The sulcular incisions were extended to teeth 12-22, 14-16, 24-26. The discard was removed and split-thickness flaps on the papillae and full thickness flaps on the buccal aspects were raised. The surgical areas were hand scaled. An osteoplasty was performed on the buccal aspects of teeth #'s 11, 21, 15, 25 to achieve a 3mm biological width as well as to reduce the prominent bony ridges over teeth 15 and 25. The surgical sites were sutured using a combination of 3.0 and 5.0 chromic gut sutures. The patient was discharged with Amoxicillin 500mg TID for seven days, Tylenol 3prn, and Chlorhexidine 0.12% BID for seven days. Tylenol was given at the request of the M.D. so as not to have blood thinning agents such as ibuprofen. (Ibuprofin was

She felt that, since adolescence, her nasal profile had dominated her face



FIGURE 13



FIGURE 14

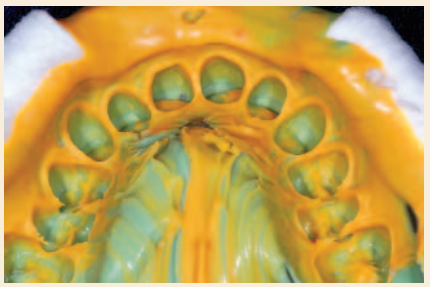

FIGURE 15



FIGURE 16



FIGURE 17



FIGURE 18

preferred for it's anti-inflammatory properties). At the post op appointment the patient did not report any complications. The patient was to be seen after the rhinoplasty for continuation of her dental treatment.

Two weeks after the gingival surgery, the patient underwent an external approach reduction rhinoplasty. The caudal septum was shortened, the cephalic lower lateral cartilages were trimmed, the dorsal hump was chiseled and rasped down, the membranous columella was reduced and osteotomies and infractures were performed.

The patient had an uneventful recovery. The 6-month result was very pleasing to the patient and she achieved her preoperative goals. She went on to report that she was no longer self conscious about her profile and nasal-labial balance (Figs. 7 & 8).

Eight weeks after her rhinoplasty, the patient returned for an evaluation.

The cosmetic surgery was healing well and though there was still inflammation, the bruising had dissipated. In addition, the outline of the procedure was beginning to reveal itself. An examination of the gingival tissues showed a balanced appearance. There was a probeable sulcus, indicating that the patient would soon be ready to proceed with the veneer portion of her case. With the plastic surgeon's permission, fresh alginate impressions were taken. They served to fabricate custom trays for part of the in-office whitening procedure and create a second diagnostic wax up from the newly prepared gingival contours (Fig. 9).

Two weeks after the gingival surgery, the patient underwent an external approach reduction rhinoplasty

A short time later the patient underwent Zoom (Discus Dental, California, USA) in-office whitening. The patient was asked to wear the prepared trays for 4 nights following completion of the procedure, to solidify the whitening procedure.

After a period of two weeks (to allow the whitening of the lower arch to stabilize), the patient attended for preparation of teeth 15-25 for full veneer coverage. The teeth were prepared using the Strategic Esthetic Protocol Kit (created by Dr. Soll in conjunction with Brassler USA). Initial depth cuts with .5mm depth cut bur (#834-021) were used and the teeth were subsequently prepared with the corresponding diamond bur (#6844-016). From the distal of 13 to the distal of 23 the interproximal contacts were removed using a mosquito bur (#8329-016). The preparation was wrapped around the contact area with the finish

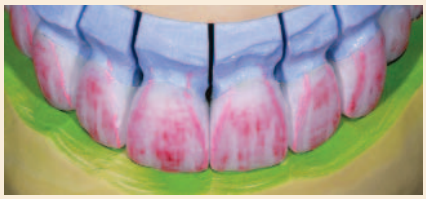

FIGURE 19

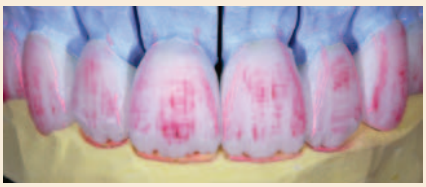

FIGURE 20

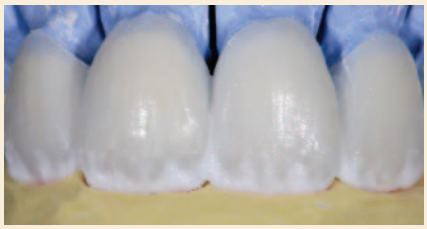

FIGURE 21



FIGURE 22



FIGURE 23



FIGURE 24

line being at the mesial or distal-lingual line angle. This preparation technique serves to place the margin in a cleansable location thereby insuring that an unsightly stain does not form. It also creates a predictable contact area that can be positioned within 5mm of the bone level, thereby insuring a healthy papilla, according to information presented by Tarnow (Fig. 10). Once all ten teeth were prepared they were inspected from the incisal and lateral views to insure that sufficient reduction was performed. In addition a putty matrix reduction guide was laid over the prepared teeth to confirm that sufficient reduction occurred according to the diagnostic wax up. As a final step, all corners and margins were rounded using a coarse soflex disk (3M Corp., Minnesota, USA) (Figs. 11–13).

To prepare for the impression, Expasyl (Kerr Corporation, California, USA) was applied to the sulcus of all prepared teeth. Expasyl serves as a non mechanical retraction system and haemostatic agent (Fig. 14). After two minutes the Expasyl was washed off and a polyvinyl impression was taken (Fig. 15). The occlusal registration was taken using the Symmetry Facial Plane Relater (Clinicians Choice, Ontario, Canada). The use of the Facial Plane Relater allows for the recording of the facial midline as well as the horizon, which are records that are required by the laboratory technician (Fig. 16).

The use of the Facial Plane Relater allows for the recording of the facial midline as well as the horizon, which are records that are required by the laboratory technician

The next step involved the fabrication of temporary restorations. These are fabricated from the diagnostic wax up and allow the doctor, technician, and patient to visualize how the final restorations will appear. Using Clearly Affinity (Clinicians Choice, Ontario, Canada), a clear polyvinyl impression of the diagnostic wax up was taken ahead of time. A spot etch was then applied, in the centre of each tooth, to assist in the adhesion of the temporaries. After 30 seconds the etch was washed off and the margin and etched portion was covered with All-Bond unfilled resin, and cured (Bisco Dental, Illinois, USA). An unfilled resin was used to make the retrieval process easier. However, because the tooth is not totally sealed, there can be intra-operative sensitivity; the patient was made aware of this. After the preps were cured, the buccal surfaces of the clear matrix were filled with a flowable resin such as Intro (Clinicians Choice, Ontario, Canada), seated over the prepared teeth, and cured through the clear matrix. The matrix was then removed and the temporaries were cured from the lingual as well. Using Brassler's Esthetic



FIGURE 25



FIGURE 26



FIGURE 27



FIGURE 28



FIGURE 29

Trimming Kit, the flash was trimmed away and the lingual and interproximal areas were cleared. The occlusion was confirmed and an alginate impression of the temps was taken for laboratory reference. At this time complete laboratory instructions were confirmed and recorded and the case was sent to the laboratory for fabrication.

Laboratory protocols

On receiving the impressions, a full visual inspection was carried out along with a customary infection control procedure which is mandatory on any new case when presented on arrival within the Laboratory.

Model preparation

Multiple plaster pours of the working prepped impression were made. It should be noted that it is essential that the impression of the preparation be taken with a stable material capable of several plaster pours and that the impression material be well supported with an even thickness of impression material within the impression tray. Integrity of the impression is essential as to allow for many separate model fabrications. Separate solid mounted models are always used to verify tissue support and the correct emergence profiles of the veneers interproximately. This model will be used to visually check for this emergence, both whilst the veneers are in the wax stage and later when pressed in ceramics.

Wax up

With the incisal silicone matrixes in place on the articulator the veneers were waxed to the correct incisal positio (Figs. 17 & 18). A labial matrix was also used to ensure accuracy of facial form. Without this protocol, consistency throughout the fabrication to the desired form will not occur and may result in a unpredictable outcome. The wax veneers were invested and pressed using the Ivoclar Vivadent protocols for IPS Empress Esthetic.

Pressing

Once pressed and cleaned, the individual veneers are fitted to the individual dies using a microscope of twenty times magnification. Marginal integrity along with no movement of the restoration on the die is paramount. As with all restorations the accurate fit will aid the longevity and vitality of the restoration (Figs. 19 & 20).

Contouring (external)

Pre-requisites of shape are carried out ensuring the facial anatomy is in total harmony within the reflective and deflective surfaces. Optimizing light reflection is critical as to allow the correct illumination of the restorations with both direct and ambient light, thus ensuring the veneers have a strong high value, exhibiting natural brilliance. Light reflection is an integral component of natural well contoured anterior restorations, without which excessive shading will result in lower value restorations and may even highlight the incorrect shaping and contour.

Contouring (internal)

It is important to ensure the

internal or dentine shaping within the restorations are completed as to harmonize with the facial anatomy. Failure to do this will result in an incorrect anatomical restoration.

Layering of ceramics
Multiple layers of incisal enamel materials are layered, with the internal layer being of a higher translucency, and a lower translucency enamel on the external, which will develop a natural opaque incisal halo (Fig. 21).

Stain and glaze
After shaping, a final glaze is undertaken using the Ivoclar Vivadent protocols for IPS Empress Esthetic. Leaving a slightly under glazed surface texture allows for manual rotary polishing, which result in desired surface texture, luster and reflection.

The following is a list of the products used to assist in creation of the veneers.

Model Plasters	Garreco
Model Die Pins	Great Lakes Orthodontics
Articulator	Sam III
Wax	Metalor Esthetic Wax
Investment	Bego
Ingot	IPS Empress Esthetic E01 Ingot(Ivoclar Vivadent)
Reduction Wheels	Perladia
Burs	Brasseler
Ceramic Materials	Ivoclar Vivdent IPS Empress Esthetic
Polishing Materials	Bredent Diamond Polish, Renfert Opal Polish

When the veneers were returned from the laboratory, they were removed from the box and checked on the hard pour to confirm fit and contour. At the insertion appointment the temporaries were removed using a mosquito bur and every contact was sectioned, being mindful not to damage the preparations (Fig. 22). This allows for easier removal. Once all of the temporary veneers were removed, a coarse sandpaper disk was used to remove any flash. The teeth were then scrubbed with a sodium-hypochlorite/pumice mixture to remove any remaining debris and for disinfection. The veneers were then tried in using Try Paste from the Rely X Veneer Cementation kit (3M Corporation, Minnesota, USA). This allows the doctor and the patient to preview the final result without the time constraints of premature setting. Once the patient approved the final appearance and cementation, the final restorations were bonded into place using the resin cement corresponding to the Try-In Paste from the Rely X Kit. The Rely X System was used because its bonding resin is not cured when applied to the tooth before cementation, making seating of the veneer very easy (Figs. 23 & 24). After the veneers were bonded according to the manufacturer's instructions, all flash and resin tags were removed (Fig. 25). The occlusion was confirmed and balanced in centric occlusion and all corresponding excursions. Prior to discharge, maxillary and mandibular impressions were taken for the fabrication of a lower occlusal guard. The patient was invited to return seven days after the insertion appointment to check for any retained resin tags, occlusal interferences, placement of the lower occlusal guard and final photographs (Figs. 26–29).

It is important to ensure the internal or dentine shaping within the restorations are completed as to harmonize with the facial anatomy

After recovery, the patient was then presented on national television, together with her before and after pictures approximately 12 weeks following the completion of her combined dental and plastic surgery treatments. Both the dentist and the plastic surgeon appeared on the show to discuss nuances of the case and dental and facial restoration in general. The patients improved aesthetics generated a favourable and strong response from the viewers and was considered a great collaborative, educational and surgically aesthetic success.

Being part of a team that transforms an individual who is to be featured on national television can be exciting but stressful-each step of the process is documented; there is little room for error. Working closely and maintaining communication with fellow professionals is crucial in achieving a desirable outcome.

Acknowledgement
The authors would like to thank Dr. Livia Silvestri for the excellent periodontal surgery result brought about by the pre prosthetic gingival recontouring. **OH**

Dr. Jordan Soll is Cosmetic Consultant to Oral Health Journal and is principle of Aesthetics in Dentistry

Dr. Stephen Mulholland is an accredited Plastic and Head and Neck Surgeon and is principle of SpaMedica.

Mr. Trevor Laingchild is an accredited Lab Technician by the AACD and principle of Burlington Dental Studio.

Oral Health welcomes this original article.

@ARTICLECATEGORY:587;